

# Clinical and pathological observations of retroperitoneal paraganglioma in 32 cases

Feiyang Xiao (✉)

Department of Pathology, Zhejiang Province Tumour Hospital, Hangzhou 310022, China

## Abstract

**Objective** The aim of the study was to investigate the clinical manifestations, pathologic features, differentiation, and diagnosis of retroperitoneal paraganglioma.

**Methods** The clinical manifestations, histopathologic morphology, immunohistologic features, treatment, and prognosis were analyzed in 32 cases of retroperitoneal paraganglioma, and the literature was reviewed.

**Results** Low back pain was the main symptom of retroperitoneal paraganglioma, and patients often presented with increased blood pressure. Blood vessels were abundant in the neoplasm of retroperitoneal paraganglioma, and pathologic diagnosis showed that the cells of tumors were rich in cytoplasm, and some were basophilic. Immunohistochemical study showed that CgA, Syn, S-100, and Ki-67 (2%–30%) were expressed, while Melan-A and CK were not. The patients were treated with surgical resection. Thirteen cases were followed up, and no recurrence or metastases have been observed.

**Conclusion** The diagnosis of retroperitoneal paraganglioma should be confirmed by morphologic features and immunophenotype. Patients should be followed-up due to the potential for malignancy.

**Key words:** retroperitoneal paraganglioma; immunohistochemistry; pathology

Received: 29 May 2015  
Revised: 1 July 2015  
Accepted: 25 August 2015

Paraganglioma is a kind of neuroendocrine neoplasm that originates from ganglion cells. Because paraganglioma is clinically rare, and the pathogenesis of pancreatic cancer is concealed, it can easily be misdiagnosed. To increase awareness of this disease, we summarized the clinical and pathologic features of 32 cases of retroperitoneal paraganglioma diagnosed in the First Affiliated Hospital, at the College of Medicine of Zhejiang University, China.

## Materials and methods

### Case source

Retroperitoneal paraganglioma was diagnosed in 32 cases after surgery in the Department of Pathology, The First Affiliated Hospital, College of Medicine of Zhejiang University (China), from January 2007 to May 2013. Basic clinical data about the patients were collected, including sex, age, clinical symptoms, laboratory examinations, pathology, and treatment.

### Reagents and detection methods

The expression of CgA (a mouse anti-human monoclonal antibody, clone: EP38), Syn (a mouse anti-human monoclonal antibody, clone: SP11), S-100 (a mouse anti-human monoclonal antibody, clone: 4C4.9), Ki-67 (a mouse anti-human monoclonal antibody, clone: 7B11), CK (a mouse anti-human monoclonal antibody, clone: AE1/AE3), and Melan (a mouse anti-human monoclonal antibody, clone: A103) was detected using manual immunohistochemical detection methods with the indicated antibodies. All of the antibodies listed above were primary antibodies at a working dilution. Secondary antibodies, a DAB Color Developing Reagent Kit, and a ready-to-use two-step (non-biotinylated) PV-9000 detection kit were purchased from Beijing Zhongshan Golden Bridge Biotechnology, China. Specimens were fixed in 10% neutral formalin, dehydrated, and embedded in paraffin. After cutting 3  $\mu$ m thick serial sections, hematoxylin and eosin (H&E) staining and microscopic observation were used to select representative paraffin sections for labeling with the antibodies. A positive biopsy was used as a positive

control, and phosphate-buffered saline was used as a negative control.

### Criteria

Cases with brown-yellow granules in the cytoplasm of the tumor cells were CgA, Syn, S-100, Melan-A, and CK positive on immunohistochemical staining. The distribution of the proteins and the staining intensity were observed, and the rate of positive staining was calculated. A staining intensity score was assigned: 0 points for colorless, 1 point for light yellow, 2 points for brown-yellow, and 3 points for brown. A score reflecting the percentage of positive cells was also assigned: 0 points for no positive cells, 1 point for positive cells  $\leq$  25%, 2 points for 26% to 50% positive cells, 3 points for 51% to 75% positive cells, and 4 points for  $>$  75% positive cells. If the product of the staining intensity score multiplied by the percentage of positive cells score was  $\geq$  2, the case was rated positive (+), and if the product  $<$  2, it was rated negative (-). Cases with brown granules in the nucleus of tumor cells were positive for Ki-67 staining. The criteria used were similar to that described above.

## Results

### General information

Among the 32 cases, 10 were men and 22 were women, with a mean age of 48.2 years (range, 14 to 69 years). Ten patients' tumors were found during medical examinations, without any symptoms; 19 patients visited the doctor with the main complaint of low back pain; two patients visited the doctor with upper abdominal pain with no apparent cause; one patient visited the doctor with hypertension symptoms. Seventeen patients had elevated blood pressure; 13 of the 17 patients had systolic blood pressure higher than 120 mmHg, with diastolic blood pressure in the normal range. The highest blood pressure among them was 270/170 mmHg. Masses were identified in 32 patients by B ultrasound or computed tomography (CT) scans; however, only three cases were correctly diagnosed compared with the pathological diagnosis. B

ultrasound or CT showed the position of the masses: 11 were in the retroperitoneal space, 10 were in the pancreas, eight were in the kidneys, two were between the liver and kidney, and one was in the anterior space of the abdominal aorta. Neurological examinations were normal for all patients.

### Gross pathological examination

Tumor size ranged from 4 cm  $\times$  3 cm  $\times$  2 cm to 11 cm  $\times$  9 cm  $\times$  8 cm. Every tumor was encapsulated; eight were cyst-solid mixed, and the others were all solid. Rich in blood vessels, 14 tumors had areas of hemorrhage, seven had necrosis, and one formed satellite nodules.

### Histomorphology

The tumor cells were in nest-like and cord-like arrangements, with abundant cytoplasm (Fig. 1a). Fifteen cases were basophils, four had extracapsular invasion, and three showed cytologic atypia. None of these cases showed vascular recidivism or lymph node metastases.

### Immunohistochemical staining

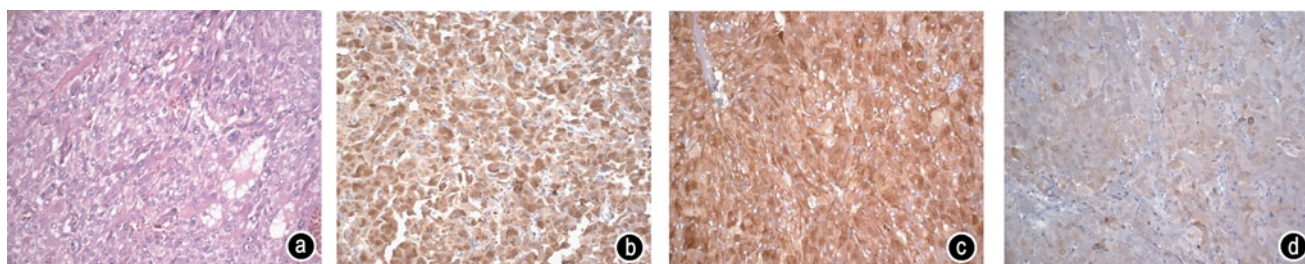
CgA was expressed in all 32 cases, with 18 cases scoring  $\geq$  3 points (Fig. 1b). Syn was also expressed in all 32 cases (Fig. 1c). S-100 was expressed in all sertoli cells (Fig. 1d), and 2% to 30% of the tumor cells expressed Ki-67. Melan-A and CK were not expressed, suggesting the tumors were of non-epithelial origin.

### Treatment and follow-up

All 32 patients underwent tumor resection. Nineteen were lost to follow up. None of the remaining 13 patients has shown signs of recurrence.

## Discussion

Primary retroperitoneal paraganglioma is a rare type of tumor originating from the neural crest cells. The actual incidence is higher than reported, because it is associated with clinical misdiagnosis and therefore many cases are overlooked. Paraganglioma that occurs in the adre-



**Fig. 1** The pathology and immunohistochemical staining of retroperitoneal paraganglioma. (a) Pathologic stain (H&E, 200 $\times$ ); (b) CgA positive (SP, 200 $\times$ ); (c) Syn positive (SP, 200 $\times$ ); (d) S-100 positive (SP, 200 $\times$ )

nal medulla is called pheochromocytoma, but it is called paraganglioma if it occurs outside the adrenal gland, and about 10% to 20% of these develop in the retroperitoneal space.

Paragangliomas can occur at any age, but it is more common in patients from 40 to 50 years old <sup>[1]</sup>, consistent with this study. Clinical evidence of the presence or absence of tumor secretion of catecholamine divides paraganglioma into functional and non-functional <sup>[2]</sup>. Clinical manifestations include a slow-growing, painless mass; lower back pain and soreness; abdominal distension and pain due to tumor compression; paroxysmal or sustained hypertension (where the systolic blood pressure is significantly higher); palpitations, dizziness, and sweating; and other symptoms due to excessive secretion of catecholamine. Some patients may have urinary urgency, frequency, and dysuria, and even painless, whole course, gross hematuria; some patients may have fever, nausea, vomiting, diarrhea, and other symptoms. Neurologic examinations are normal.

Correct preoperative qualitative diagnosis of retroperitoneal paraganglioma is very difficult. Locating and diagnosing these tumors mainly rely on B ultrasound and CT examination, or some patients could choose magnetic resonance imaging (MRI) or positron emission tomography (PET)-CT. Zhang GJ *et al* <sup>[1]</sup> reported that a CT examination could reveal characteristic changes. Gross examination shows that the tumors are a round or oval-shaped mass, and they are usually large, ranging from 5 to 10 cm in diameter, although there is a report of a tumor up to 25 cm in diameter <sup>[3]</sup>. The tumors are usually solitary, and have a clear boundary and capsule; some tumors have an intact capsule, while the boundary of malignant tumors is not clear. Six out of our 32 cases had capsular invasion, but to a lesser extent.

The tumors have a nodular surface, with a notched, lobulated structure and a dark red color, with irregular or smooth edges. The tumors have a dark section, and are rich in blood vessels, often accompanied by necrosis and cystic lesions, and they may have calcifications, and occasionally, satellite nodules.

Microscopically, the tumor cells are usually well-differentiated, in nested cords with a dendritic arrangement. The inner layer consists of the main cells, while the outer layer consists of pillar cells in a monolayer. The shape of the tumor cells is homogeneous, and they are larger than normal cells, with abundant exquisite or stippled chromatin; the cytoplasm is acidophilic or basophilic, close to transparent, and has an obscure boundary. The round or oval nuclei of the tumor cells are usually eccentrically located, although some might be in the center. The nucleoplasm is usually loose and darkly stained; nucleoli might be prominent and atypical. Nine point three percent of the patients in our study had inconspicuous nucleoli or

atypical nucleoli.

The interstitial cells are rich in blood vessels, mainly consisting of ectatic thin-walled sinus-like blood vessels, with argyrophilic fiber dyeing showing a characteristic grid-like structure. Under an electron microscope there are two types of tumor cells, light and dark, and the tumor cells contain neuroendocrine particles, with a diameter of 100 to 200 nm.

Diagnosis of paraganglioma can be confirmed only if CgA and Syn are expressed in the retroperitoneal paraganglioma tissue, S-100 is expressed in the Sertoli cells, and CK and Melan-A are not expressed. Some studies showed that the positive expression of S-100 is associated with a favorable prognosis, but other studies have also found many Sertoli cells in malignant cases <sup>[3]</sup>. In this study, the positive rate of Ki-67 ranged from 2% to 30%, suggesting that paraganglioma have proliferative activity, but the activity is not high.

It is controversial whether paraganglioma is benign or malignant. Paragangliomas should not be judged solely on their pathological characteristics when deciding between benign or malignant. Instead, all paraganglioma should be regarded as potentially malignant or low-grade malignant. Generally, recurrence or metastasis is the criterion for malignant paraganglioma, and the most reliable indicator is lymph node metastasis. Capsular and vascular invasion are relevant in a relative sense, and wide capsular invasion or tumor invasion could be diagnosed as malignant paraganglioma <sup>[4]</sup>. Joynt *et al* <sup>[5]</sup> reported that most cases of paraganglioma are benign, and surgery is the primary therapy.

In recent years, Huy *et al* <sup>[6]</sup> reported treating 88 patients with malignant jugular paraganglioma with radiotherapy and obtained good results, but whether radiotherapy is suitable for retroperitoneal paraganglioma tumors is unknown. Bravo *et al* <sup>[7]</sup> reported one case of a paraganglioma patient with liver metastases treated with chemotherapy, and obtained good results and few adverse reactions. Other treatments remain to be further studied. In this study, all 32 patients underwent tumor resection, and the 13 patients who have been followed up are still alive. Because of the potential for paragangliomas to be malignant, postoperative follow-up is particularly important.

### Conflicts of interest

The author indicated no potential conflicts of interest.

### References

1. Zhang GJ, Lv HJ. CT findings and diagnostic value of retroperitoneal paraganglioma. *Ningxia Med J (Chinese)*, 2013, 35: 301-302.
2. Shi SK. CT diagnosis and differential diagnosis of primary retroperitoneal paraganglioma. *Inter J Med Radiol (Chinese)*, 2010, 33:

- 249–252.
3. Zhang HL, Yang F, Fang YQ, *et al*. Non-functional paraganglioma of the bladder: a case report and review of the literature. *Chin J Endourol (Electr Edit)(Chinese)*, 2012, 6: 467–470.
  4. Shi HY, Yuan LH, Li ZG, *et al*. Paraganglioma diagnosis and treatment progress. *Pract J Med (Chinese)*, 2010, 26: 711–713.
  5. Joynt KE, Moslehi JJ, Baughman KL. Paragangliomas: etiology, presentation, and management. *Catdiol Rev*, 2009, 17: 159–164.
  6. Huy PT, Kania R, Duet M, *et al*. Evolving concepts in the management of jugular paraganglioma: a comparison of radiotherapy and surgery in 88 cases. *Skull Base*, 2009, 19: 83–91.
  7. Bravo EL, Kalmadi SR, Gill I. Clinical utility of temozolomide in the treatment of malignant paraganglioma: a preliminary report. *Horm Metab Res*, 2009, 41: 703–706.

**DOI 10.1007/s10330-015-0097-5**

**Cite this article as:** Xiao FY. Clinical and pathological observations of retroperitoneal paraganglioma in 32 cases. *Oncol Transl Med*, 2015, 1: 218–221.