

Sex-related changes in tumor consistency in prolactinoma patients after bromocriptine pretreatment*

Yimin Huang, Feng Hu, Kang Wu, Juan Chen, Ran Li, Hao Xu, Ting Lei (✉)

Department of Neurosurgery, Tongji Hospital, Tongji Medical College, Huazhong University of Science and Technology, Wuhan 430030, China

Abstract

Objective It has long been reported that prolactinomas treated with bromocriptine increase fibrosis and may affect surgical outcomes. We retrospectively studied 238 consecutive patients with histopathologically confirmed prolactinomas undergoing microsurgery in a single neurosurgery department of Tongji Hospital (Wuhan, China) from 2012 to 2015 in order to evaluate tumor consistency changes after bromocriptine pretreatment and surgical outcomes.

Methods We divided the patients into four groups: males in the dopamine agonist (DA) group, females in the DA group, males in the no DA group, and females in the no DA group, and we compared the surgery process, specimen Masson staining, and clinical outcomes of the four groups. According to a previously published classification, the operative notes from an experienced neurosurgeon were reviewed to classify the consistency of tumors as “fibrous” or “nonfibrous”.

Results No differences in tumor consistency were found in male patients with or without DA treatment. However, in female patients with DA treatment, tumors were likely to be harder in texture than the tumors of female patients without DA treatment. Despite tumor consistency differences between sexes, the tumor biological remission rate was similar between groups, as was the rate of tumor resection.

Discussion Our study indicates that preoperative DA therapy impacts tumor consistency in female patients but not male patients. Although the surgical and histopathological outcomes are not influenced, these findings may provide useful information for the choice of operative approach and surgery process for pituitary adenoma.

Key words: prolactinoma; bromocriptine; tumor consistency; surgical outcomes

Received: 4 August 2016
Revised: 4 September 2016
Accepted: 25 September 2016

Pituitary adenoma, a type of benign tumor occurring in the pituitary gland, accounts for 10%–20% of central nervous system tumors^[1]. Prolactinoma, which has the highest incidence rate (40%) in pituitary adenoma, is caused by pituitary prolactin hormone secretory cell hyperplasia^[2–3]. Prolactinomas are unique, for they are pituitary tumors that can be treated with medical therapy. Dopamine agonists (DA) have been the preferred drug therapy of prolactinoma for many years, with bromocriptine as the treatment of choice^[4–6]. Since 1985, bromocriptine has been examined as part of a prospective multicenter trial and has gradually become the first-line medication to treat prolactinomas^[7].

However, in many cases, patients of either sex do not experience normalization of prolactin levels or obvious tumor shrinkage as confirmed by MRI, are classified as resistant to the DA therapy, and receive surgical treatment^[4, 8–10]. In many clinical centers, neurosurgeons have found that the tumor consistency in some patients tends to be tougher and more tensile or, conversely, softer after long-term treatment with DA agonist. Previous studies have demonstrated that after DA therapy, tumor cells and interstitial tissue undergo tumor cell shrinkage and interstitial tissue and perivascular fibrosis^[11–17], which has generated some controversy regarding first-line therapy^[18–19]. In our clinical experience, we found that the con-

✉ Correspondence to: Ting Lei. Email: tlei@tjh.tjmu.edu.cn

* Supported by a grant from the National Natural Sciences Foundation of China (No. 81270865).

© 2016 Huazhong University of Science and Technology

Table 1 Demographics of patients in this study

Groups	DA (<i>n</i> = 106)		No DA (<i>n</i> = 132)	
	Male	Female	Male	Female
Number of patients	11	95	45	87
Age (years)	28.7 ± 10.0	29.1 ± 9.5	31.2 ± 9.6	29.4 ± 9.4
Pre-operative PRL level (ng/mL)	1397.8 ± 544.4	268.4 ± 27.8	1952.2 ± 354.0	344.1 ± 75.0
% Patients presenting with amenorrhea	N/A	74.7%	N/A	67.8%
% Patients presenting with sexual dysfunction	81.8%	N/A	75.6%	N/A
% Patients with macroprolactinoma	61%		68%	

sistency of tumors is different between males and females after bromocriptine pretreatment, and the surgical outcomes are not identical.

In this study, our aim was to study sex differences in the relationship between DA pretreatment and tumor consistency. In our clinical center, in order to evaluate the choice of bromocriptine in treating male or female patients with prolactinomas, we assessed prolactinoma tumor consistency after DA therapy and the correlation of DA pretreatment with postoperative remission rates between the two sexes.

Patients and methods

Patient population

In our study, 238 patients were included, all of whom underwent transsphenoidal surgery with histopathologically confirmed prolactinomas from 2012 to 2015 at Tongji Hospital, Wuhan, China. Demographics included: 50 patients (Male, 5; Female, 45) with microprolactinomas and 188 patients (Male, 51; Female, 137) with macroprolactinomas. Of these, 106 patients (Male, 11; Female, 95) previously received DA treatment (> 3 months) and 132 (Male, 45; Female, 87) directly underwent surgery because of tumor local compression, intolerance to bromocriptine, or strong desire for reproduction. Of the 106 patients exposed to bromocriptine, 2 (Male, 0; Female, 2) also received Gamma Knife treatment. The rest of the patients were treated by bromocriptine intake only. The total mean bromocriptine cumulative dose in all patients was 1.2 mg, ranging from 0.25 to 1.5 mg per day, over 90–350 days. Demographic data were shown in Table 1.

Data collection and analysis

All preoperative and postoperative radiographic tests were obtained from our institution, and postoperative MRI scans were collected in the outpatient department when patients were referred to physicians. Initial pre, peri, and postoperative endocrine data were obtained from Tongji Hospital medical records and from records of referring and consulting physicians. Initial prolactin level refers to the earliest known documented level prior to medical therapy. The hormone statics were evaluated

within 5 days before surgery, and the postoperative prolactin (PRL) levels were tested 2 days to 3 months after surgery and defined as the immediate postoperative PRL levels. As in a previous classification^[20], the patients were separated into two groups: “DA” if they had received preoperative treatment with bromocriptine and “no DA” if surgery was the first-line definitive therapy and there was no known exposure to bromocriptine. The exclusion criteria included missing information of preoperative prolactin levels, patients with a history of prior surgery or radiotherapy, or missing information of prolactin levels after surgical treatment.

Tumor consistency and Masson staining value

According to classification by Mennucci^[15], tumor consistency was described by the surgeon in the operative notes as “firm”, “solid”, “difficult to resection”, “hard”, “close adhesion to peri-tissue”, or “difficult to resect tumor by aspirator” indicating fibrous consistency, or “soft”, “easily resect tumor by aspirator”, or “typical consistency” indicating nonfibrous consistency. We collected prolactinoma tumor tissue from 25 patients to stain using the Masson procedure. In order to concisely conclude the Masson staining result, the fibrous positive was defined as high fibrous expression in a single field.

Radiographic and hormone data analysis

The radiographic tumor volume data were acquired by high resolution MRI and estimated by tracing the tumor using transparent film and measuring mean diameter of each section. The tumor resection rate data were collected by comparing the postoperative and preoperative tumor volume, using an analysis method known as the platform-like volume calculation formula developed by Wang^[21]. The surgery efficacy was determined by immediate PRL level and MRI data of the patient more than 6 months after surgery. Patients who necessarily received postoperative bromocriptine treatment were estimated during the postoperative period prior to bromocriptine treatment. Curative conditions were defined as follows: normal PRL levels, menstruation recovery in females, and disappearance of lactation symptoms. Ineffective conditions were defined as follows: PRL level reduction rate < 80% or PRL

level unchanged or higher.

Statistical analysis

The characteristics of tumor consistency, sex, presenting symptoms, preoperative prolactin levels, and rates of tumor resection were compared between groups using the chi-squared test. Bonferroni corrections were performed for subgroup analyses when relevant. $P < 0.05$ was considered statistically significant. All continuous variables were presented as mean \pm SE.

Results

Tumor consistency

The tumor consistency of patients preoperatively treated with DA was more likely to be described as “fibrous”. About 39.6% of patients in the total DA group had tumors depicted as “fibrous” consistency compared with 12.1% of patients in the no DA group ($P < 0.05$). When the patients were analyzed by sex, male and female patients showed different tendencies of tumor consistency change after DA treatment. In female patients, the “fibrous” consistency description was more likely to be found in the DA group than in the no DA group (40% vs. 16%, $P < 0.05$, Table 2). In male patients, the “fibrous” consistency description was generally less likely to be found in the DA group than in the no DA group, but there was no significant difference between them (43% vs. 47%, $P > 0.05$, Table 2). To adjust for the effect of the significantly higher pre-therapy PRL levels seen in the DA group, we performed two subgroup analyses. In patients with baseline PRL levels lower than 1000 ng/mL, the proportion of “fibrous” tumor consistency was less in the no DA pretreatment group than in the DA group (0% vs. 39.3%, $P < 0.05$). In other words, when male patients’ PRL levels preceding surgery were less than 1000 ng/mL, the tumor tissue consistency of those who received DA was more likely to be nonfibrous and easily resected by aspirator. Among female patients, regardless of preoperative PRL level, those treated with bromocriptine prior to transphenoidal surgery had remarkably more “fibrous” tumor consistency. The representative intraoperative findings of patients were also shown in Fig. 1.

Table 2 Tumor consistency of prolactinoma patients

Gender	DA pretreatment	Number of patients	Number of fibrous tumor	Chi-square test
Male	DA	11	2	$P = 0.680$
	No DA	45	6	$(P > 0.05)$
Female	DA	95	38	$P = 0.003$
	No DA	87	14	$(P < 0.05)$

Table 3 Masson staining of tumor tissue slices

Gender	DA pretreatment	Number of patients	Number of fibrous positive tumors	Chi-square test
Male	DA	5	1	$P = 0.293$
	No DA	7	4	
Female	DA	8	7	$P = 0.217$
	No DA	5	2	

Masson staining of tumor tissue slices

From male patients in the DA group, 20% (1/5) of specimens were fibrous positive, compared with 57% (4/7) in the male control group. Compared with 40% (2/5) fibrous positive specimens in female patients of the no DA group, specimens from those in the DA group were 87.5% (7/8) fibrous positive (Table 3). Typical samples were shown in Fig. 2.

Biological and radiographic remission rate

The tumor postoperative biological remission rate was not influenced by DA pretreatment among female prolactinoma patients. The number of females in the DA group who had total biological remission was 81.3% (74/91), similar to the 88.0% (73/83) in the no DA group ($P > 0.05$). Nevertheless, 13.2% of female patients in the DA group and 11.0% in the no DA group had partial biological remission (13.2% vs. 11%, $P > 0.05$, Table 4).

According to radiological reports written by several experienced radiologists, the tumor volumes were pre- and postoperatively evaluated to analyze the tumor resection rate. Regardless of preoperative tumor size, male patients in the DA group showed similar tumor resection rates to male patients in the no DA group (0.46 ± 0.69 vs. 0.88 ± 0.13 , $P > 0.05$, Table 5). As shown in the MRI in Fig. 3 and 4, the male macroprolactinoma patients who received DA pretreatment had total tumor resection, and the male macroprolactinoma patient in the no DA group

Table 4 Prolactinoma patients’ postoperative immediate PRL remission rate

Gender	DA pretreatment	Number of patients	Number of total remission	Number of partial remission	Number of no remission	Chi-square test
Male	DA	11	2	3	5	$P = 0.000$
	No DA	45	16	21	4	$(P < 0.01)$
Female	DA	95	78	12	5	$P = 0.254$
	No DA	87	77	9	1	$(P > 0.05)$

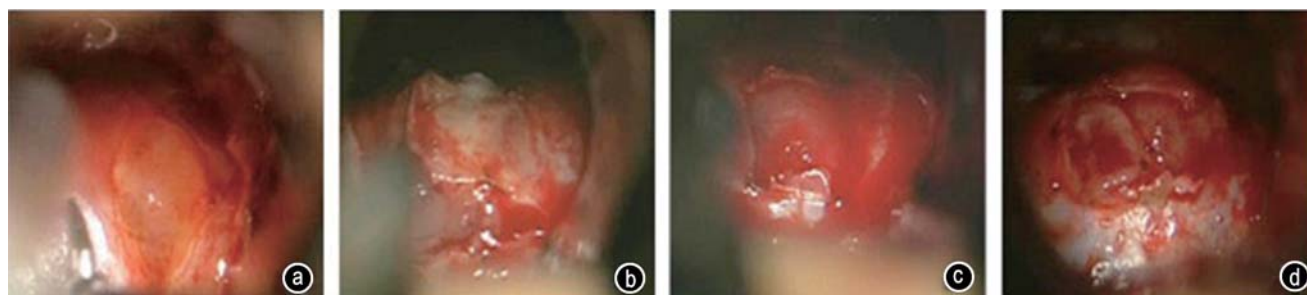

Fig. 1 Typical intraoperative findings in prolactinoma patients. (a and b) Male patients' tumors in both the no DA and DA groups were typically translucent and soft upon incision of the dura mater, which allowed for easy resection by aspirator. (c and d) Tumor of female patient in the DA group was more substantial and solid with fiber separation, and we had to scrape the tumor piecemeal. The texture of the tumor of a female patient in the no DA group was typical and removed by aspirator

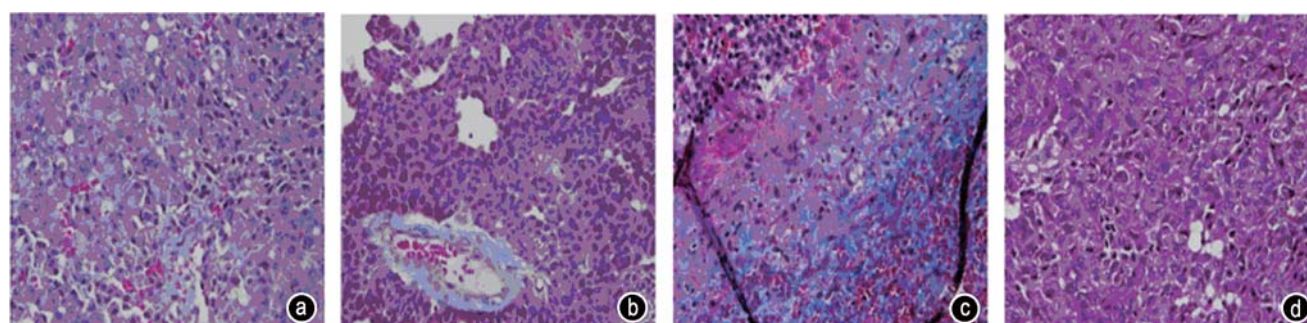


Fig. 2 Masson staining of prolactinoma patients' tumor slices. Tumor tissues of male patients in the DA group (a) showed more tumor cells and vacuole-like cells in single field than those of male patients in the no DA group (b). Interstitial fibrosis (blue staining) was rare in these two slices, and the perivascular fibrosis was not particularly abundant (b). Interstitial fibrosis was much more highly expressed in female patients in the DA group (c) than in females in the no DA group (d)

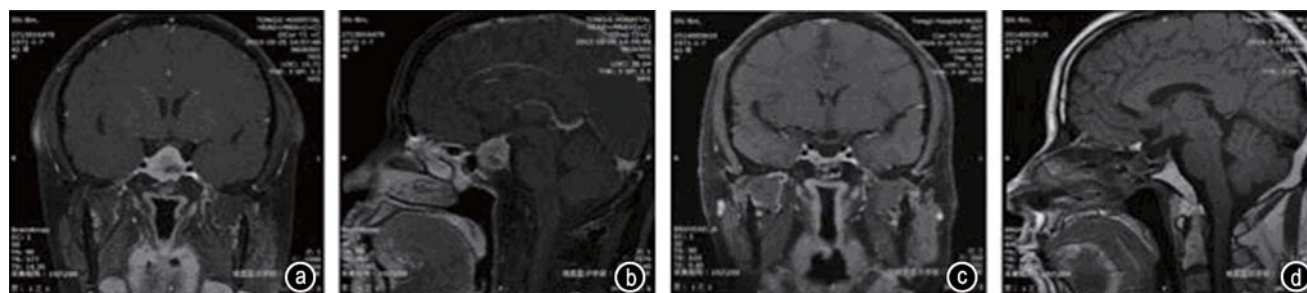


Fig. 3 Representative preoperative (a and b) and postoperative (c and d) MRI of a male prolactinoma patient with DA pretreatment

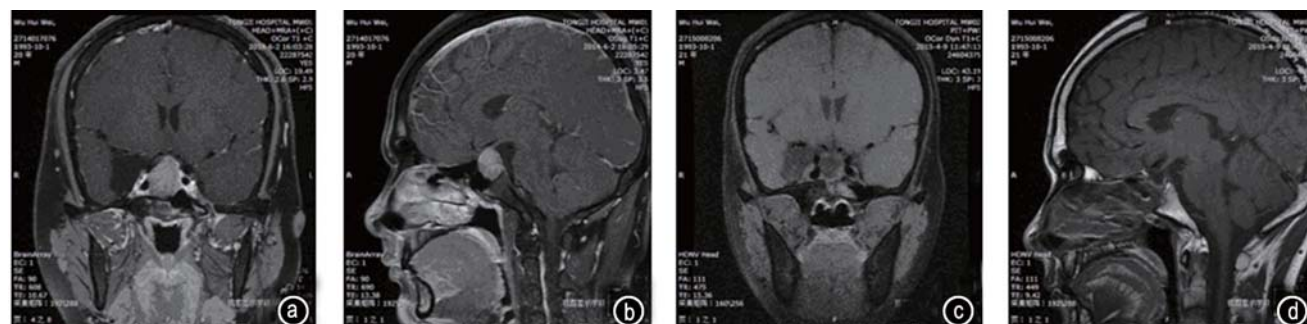


Fig. 4 Representative preoperative (a and b) and postoperative (c and d) MRI of a male prolactinoma patient without DA pretreatment

Table 5 Prolactinoma patients' tumor resection rate

Gender	DA pretreatment	Number of patients	Tumor resection rate	Chi-square test
Male	DA	11	0.46 ± 0.69	$P = 0.319$
	No DA	45	0.88 ± 0.13	$(P > 0.05)$
Female	DA	95	0.72 ± 0.54	$P = 0.267$
	No DA	87	0.78 ± 0.23	$(P > 0.05)$

also had radiological total tumor removal.

Discussion

Our data suggest that bromocriptine pretreatment increases the tendency of fibrous prolactinoma formation in female patients compared with male patients. We demonstrate that pituitary adenoma texture is sex-related, suggesting that the choice of treatment can be more flexible for male prolactinoma patients. Furthermore, in terms of female prolactinoma patients, contrary to the idea that the increased fibrosis observed in bromocriptine-treated tumors may increase surgery difficulty and the risk of damage to peripheral structures (e.g. normal pituitary), the hormone remission rates and tumor resection rates were identical between the DA and no DA groups. In terms of male prolactinoma patients, DA pretreatment did not influence the surgical outcome or biological remission rate in our clinical center.

Several studies during the last two decades have reported tremendous morphological changes occurring in prolactinomas after treatment with bromocriptine. These changes include: (1) tumor cells often appearing hypercellular because of remarkable cell shrinkage observed by light microscopy; (2) cells exhibiting a significant reduction in cytoplasmic volume, nuclear hyperchromasia, and an increase in the nuclear/cytoplasmic ratio; and (3) long-term treatment causing an increase in extensive interstitial and perivascular fibrosis [11, 13–14, 16]. Our data describe the increased hardness of the tumor from the aspect of surgeon's feeling during the operation process, which in general demonstrates the development of fibrosis in PRL tumors following bromocriptine premedication (Fig. 2c and 2d). Previous studies have not compared male and female patients separately, so the existence of sex differences was unknown. This study suggests that unlike in female patients, the consistency of male patient tumors will not develop a firm texture after pre-surgical bromocriptine treatment. In some cases, particularly those with ordinarily high levels of PRL (under 1000 ng/mL), bromocriptine use pre-surgery may in fact cause soft tumor texture (data not shown).

Prolactinomas are relatively uncommon in men compared to women and are ordinarily large and invasive tumors with high PRL levels at the time of diagnosis. Dopamine

agonist therapy can normalize PRL level regardless of tumor size in most men with prolactinomas, although bromocriptine-resistant tumors may be more frequently encountered in men [22–24]. Male patients in the DA group with ordinarily high PRL levels had soft tumors, which may also indicate that prolactinoma consistency is correlated with pre-surgical PRL level. Our Masson staining of tumor specimens suggests that expression of fibrosis in male tumors is not influenced by bromocriptine therapy in comparison with female patients (Fig. 2). We suggest the possible explanation that fibrous formation deficiency occurs in male patients receiving dopamine agonists. Thus, if a tumor is DA-resistant, the structure of the tumor will much more easily collapse, as it is soft because of the lack of interstitial fibrous. In addition, prolactin secreted from the tumor cells is released through the microvasculature to the blood, together with mild prolactin secretion activity due to shrinkage of tumor cells, which eventually presents as ordinarily high, but not extremely high, PRL level.

Compared with female patients, bromocriptine-resistant tumors occur much more frequent in men [22, 25]. Additionally, previous studies showed that male patients' tumors tend to express much more Ki-67 and PCNA, two markers for proliferative activity in tumors [26]. Furthermore, a recent study illustrated that PRL tumors in men are characterized by lower ER- α expression, which is related to higher resistance to treatment and worse prognosis [27]. Some researchers discovered a significant down-regulation of the TGF- β /Smad signaling cascade in DA-resistant prolactinomas, which is the main signaling pathway involved in fibrosis in many organs, including kidney, liver, and lung [28–32]. In summary, we confer that the different changes in tumor consistency between sexes after DA treatment may be caused by different expression of TGF- β /Smad and ER- α between men and women. However, the specific mechanisms of the different results observed in male and female prolactinoma patients remain unclear, requiring further research.

That bromocriptine is related to tumor perivascular/interstitial fibrosis has been reported, but whether fibrosis has a positive or a negative influence on the treatment of prolactinomas is an ongoing debate. In 1982, Landolt first reported that bromocriptine treatment prior to surgery can negatively affect the outcome of microsurgery [33]. The choice of bromocriptine premedication has become a critical question. Surgeons such as Derome and Esiri successively reported the similar discovery that bromocriptine pretreatment may negatively affect operation outcomes [34]. However, the study of DA agonist premedication has shown different results since the 1990s. Turner, Hubbard, and Fahlbusch published their long-term single institutional study reporting that bromocriptine treatment prior to microsurgery had no significant impact on

tumor resection effect and prognosis [13, 35–38]. Conversely, it has been reported that bromocriptine treatment prior to surgery seemed to improve surgical outcome possibly by inducing tumor regression [8, 18, 20, 37].

A possible explanation of these contradictory conclusions is the lack of comparability between the DA group and the no DA group in the former study because the patients were separated only by whether they had received DA pretreatment. The clinical characteristics of patients, such as tumor volume, preoperative PRL level, and sex, were significantly different between groups, which can eventually affect prolactinoma operation outcomes. Further, the entirely contrary results of these reports could be attributed to the small sample number of cases. There have been few multicenter studies using large sample sizes to examine the choice of bromocriptine prior to surgery and related factors. Otherwise, the development of microsurgery techniques, advanced neuronavigation technology, and the application of endoscope-assisted microneurosurgery are important factors that influence the results.

Our results indicate that pretreatment with bromocriptine does not affect surgical outcome as much as previously believed, regardless of patients' sex, and that the biological remission rate does not differ between groups, suggesting that the formation of fibrosis in these patients is irrelevant to their overall outcome.

However, this conclusion is based on an experienced surgeon who performed the microsurgery, along with the tacit cooperation of our surgical team, and we discovered that the presence of fibrosis in the tumor often requires more time and experience to detach the tumor from neighboring tissue. The complexity of hemostasis during the process of separating and resecting tumor was also increased when the tumor fibrous formation was promoted by bromocriptine premedication, according to our and other institutes' surgery reports. These procedures also require more time of the whole surgery, which means the possibility of perioperative events would increase as well. The different morphology of tumor consistency between sexes still can be used as reference for the choice of operative approach. When treating male prolactinoma patients, DA therapy could be more positively chosen by the doctor for the low incidence of tumor consistency changes and negative effects on follow-up operation. In addition, tumors described as fibrous or "hard" may not easily be removed by junior doctors using the transsphenoidal approach; therefore, the level of experience in this study may also provide a reference for choice of surgical approach.

This study is limited by its retrospective nature and small sample size, due to most of the surgery are performed in this year. Thus, long-term follow-up was needed to evaluate the surgical outcome in each group. How-

ever, the findings of this study may provide significant reference information for young neurosurgeons, which may offer the most benefit in dealing with nonfibrous tumors. Finally, differences in the outcome of DA pretreatment between male and female patients still require further multicenter study.

Conclusion

Our study indicates that preoperative dopamine agonist therapy impacts tumor consistency in female but not male prolactinoma patients. Although the surgical outcomes and histopathological outcomes were not influenced, our findings may provide some useful information in the choice of pituitary adenoma surgical process. Finally, the mechanisms underlying these differences warrant further exploration.

Conflicts of interest

The authors indicated no potential conflicts of interest.

References

- Gillam MP, Molitch ME, Lombardi G, *et al.* Advances in the treatment of prolactinomas. *Endocr Rev*, 2006, 27: 485–534.
- Colao A. Pituitary tumours: the prolactinoma. *Best Pract Res Clin Endocrinol Metab*, 2009, 23: 575–596.
- Kars M, Dekkers OM, Pereira AM, *et al.* Update in prolactinomas. *Neth J Med*, 2010, 68: 104–112.
- Klibanski A. Clinical practice. Prolactinomas. *N Engl J Med*, 2010, 362: 1219–1226.
- Reichlin S. The prolactinoma problem. *N Engl J Med*, 1979, 300: 313–315.
- Vance ML, Evans WS, Thorner MO. Drugs five years later. Bromocriptine. *Ann Intern Med*, 1984, 100: 78–91.
- Molitch ME, Elton RL, Blackwell RE, *et al.* Bromocriptine as primary therapy for prolactin-secreting macroadenomas: results of a prospective multicenter study. *J Clin Endocrinol Metab*, 1985, 60: 698–705.
- Hamilton DK, Vance ML, Boulos PT, *et al.* Surgical outcomes in hyporesponsive prolactinomas: analysis of patients with resistance or intolerance to dopamine agonists. *Pituitary*, 2005, 8: 53–60.
- Losa M, Mortini P, Barzaghi R, *et al.* Surgical treatment of prolactin-secreting pituitary adenomas: early results and long-term outcome. *J Clin Endocrinol Metab*, 2002, 87: 3180–3186.
- Smith TR, Hulou MM, Huang KT, *et al.* Current indications for the surgical treatment of prolactinomas. *J Clin Neurosci*, 2015, 22: 1785–1791.
- Anniko M, Wersäll J. Morphological changes in bromocriptine-treated pituitary tumours. *Acta Otolaryngol*, 1983, 96: 337–353.
- Asa SL, Ezzat S. Medical management of pituitary adenomas: structural and ultrastructural changes. *Pituitary*, 2002, 5: 133–139.
- Hubbard JL, Scheithauer BW, Abboud CF, *et al.* Prolactin-secreting adenomas: the preoperative response to bromocriptine treatment and surgical outcome. *J Neurosurg*, 1987, 67: 816–821.
- Kontogeorgos G, Horvath E, Kovacs K, *et al.* Morphologic changes of prolactin-producing pituitary adenomas after short treatment with dopamine agonists. *Acta Neuropathol*, 2006, 111: 46–52.
- Menucci M, Quiñones-Hinojosa A, Burger P, *et al.* Effect of dopaminergic drug treatment on surgical findings in prolactinomas. *Pituitary*,

- 2011, 14: 68–74.
16. Scanarini M. Morphological changes in prolactinoma induced by bromocriptine treatment. *Minerva Endocrinol (Italian)*, 1990, 15: 13–15.
17. Sobrinho LG, Nunes MC, Santos MA, *et al.* Radiological evidence for regression of prolactinoma after treatment with bromocriptine. *Lancet*, 1978, 2: 257–258.
18. Chakraborty S, Dehdashti AR. Does the medical treatment for prolactinoma remain the standard of care? *Acta Neurochir (Wien)*, 2016, 158: 943–944.
19. Molitch ME, Thorner MO, Wilson C. Management of prolactinomas. *J Clin Endocrinol Metab*, 1997, 82: 996–1000.
20. Sughrue ME, Chang EF, Tyrell JB, *et al.* Pre-operative dopamine agonist therapy improves post-operative tumor control following prolactinoma resection. *Pituitary*, 2009, 12: 158–164.
21. Wang S, Lin S, Wei L, *et al.* Analysis of operative efficacy for giant pituitary adenoma. *BMC Surg*, 2014, 14: 59.
22. Arasho BD, Schaller B, Sandu N, *et al.* Gender-related differences in pituitary adenomas. *Exp Clin Endocrinol Diabetes*, 2009, 117: 567–572.
23. Nishioka H, Haraoka J, Akada K, *et al.* Gender-related differences in prolactin secretion in pituitary prolactinomas. *Neuroradiology*, 2002, 44: 407–410.
24. Schaller B. Gender-related differences in prolactinomas. A clinico-pathological study. *Neuro Endocrinol Lett*, 2005, 26: 152–159.
25. Trouillas J, Delgrange E, Jouanneau E, *et al.* Prolactinoma in man: clinical and histological characteristics. *Ann Endocrinol (Paris)(French)*, 2000, 61: 253–257.
26. Delgrange E, Trouillas J, Maiter D, *et al.* Sex-related difference in the growth of prolactinomas: a clinical and proliferation marker study. *J Clin Endocrinol Metab*, 1997, 82: 2102–2107.
27. Delgrange E, Vasiljevic A, Wierinckx A, *et al.* Expression of estrogen receptor alpha is associated with prolactin pituitary tumor prognosis and supports the sex-related difference in tumor growth. *Eur J Endocrinol*, 2015, 172: 791–801.
28. Li Z, Liu Q, Li C, *et al.* The role of TGF-beta/Smad signaling in dopamine agonist-resistant prolactinomas. *Mol Cell Endocrinol*, 2015, 402: 64–71.
29. Meng XM, Tang PM, Li J, *et al.* TGF-beta/Smad signaling in renal fibrosis. *Front Physiol*, 2015, 6: 82.
30. Recouvreux MV, Lapyckyj L, Camilletti MA, *et al.* Sex differences in the pituitary transforming growth factor-beta1 system: studies in a model of resistant prolactinomas. *Endocrinology*, 2013, 154: 4192–4205.
31. Saito A, Nagase T. Hippo and TGF-beta interplay in the lung field. *Am J Physiol Lung Cell Mol Physiol*, 2015, 309: L756–L767.
32. Xu F, Liu C, Zhou D, *et al.* TGF-beta/SMAD pathway and its regulation in hepatic fibrosis. *J Histochem Cytochem*, 2016, 64: 157–167.
33. Landolt AM, Keller PJ, Froesch ER, *et al.* Bromocriptine: Does it jeopardise the result of later surgery for prolactinomas? *Lancet*, 1982, 2: 657–658.
34. Esiri MM, Bevan JS, Burke CW, *et al.* Effect of bromocriptine treatment on the fibrous tissue content of prolactin-secreting and non-functioning macroadenomas of the pituitary gland. *J Clin Endocrinol Metab*, 1986, 63: 383–388.
35. Fahlbusch R, Buchfelder M, Schrell U. Short-term preoperative treatment of macroprolactinomas by dopamine agonists. *J Neurosurg*, 1987, 67: 807–815.
36. Liu J, Li C, Xiao Q, *et al.* Comparison of pituitary adenomas in elderly and younger adults: Clinical characteristics, surgical outcomes, and prognosis. *J Am Geriatr Soc*, 2015, 63: 1924–1930.
37. Perrin G, Treluyer C, Trouillas J, *et al.* Surgical outcome and pathological effects of bromocriptine preoperative treatment in prolactinomas. *Pathol Res Pract*, 1991, 187: 587–592.
38. Turner HE, Adams CB, Wass JA. Trans-sphenoidal surgery for microprolactinoma: an acceptable alternative to dopamine agonists? *Eur J Endocrinol*, 1999, 140: 43–47.

DOI 10.1007/s10330-016-0180-6

Cite this article as: Huang YM, Hu F, Wu K, *et al.* Sex-related changes in tumor consistency in prolactinoma patients after bromocriptine pretreatment. *Oncol Transl Med*, 2016, 2: 203–209.