

Spontaneous rupture of the giant gastric stromal tumor (> 35 cm) as a rare cause of acute abdomen: a case report

Libo Feng, Dong Xia, Qing Liu, Yi Liu, Liang Xu

Department of Gastrointestinal Surgery, The Affiliated Hospital of Luzhou Medical College, Luzhou 646000, China

Received: 25 February 2014 / Revised: 27 February 2014 / Accepted: 10 March 2014

© Huazhong University of Science and Technology 2014

Abstract A case of spontaneous rupture of giant gastrointestinal stromal tumor (GIST) of stomach causing acute abdomen is described below. A male patient with abdominal mass presented with symptoms and signs of acute abdomen after admitting for 1 day. After preoperative management and evaluation, an exploratory laparotomy was performed, where rupture of a huge tumor in the stomach was found. A subtotal gastrectomy including the mass was performed and the final immunohistochemical examination verified that the neoplasm was a high risk GIST. The postoperative period was uneventful and the patient received treatment with imatinib mesylate, and regular follow-up without recurrence.

Key words gastric stromal tumor; rupture; acute abdomen; surgery

Gastrointestinal stromal tumors (GIST) are rare mesenchymal tumors arising from almost the whole gastrointestinal (GI) tract [1], as well as mesentery, omentum or retroperitoneum [2]. The stomach (60%–70%) and the small bowel (20%–30%) are the most frequent sites of GISTs [3–4]. Most of them harbor an activating c-kit gene mutation, about 85%, 3% to 5% carry a mutation in the PDGFRA gene, the rest contain the both [5–7]. GISTs are located typically in the submucosa of the GI tract wall, and the sizes are from a few millimeters to dozens of centimeters, which correlate with symptoms. Abdominal mass, pain and bleeding are the most frequent representations [8]. Abdomen computer tomography (CT) and endoscopic ultrasound play a primary but extremely significant role in finding and evaluating these tumors [9–10], whereas final accurate diagnosis depends on the immunohistochemical detection, most showing positive for CD117 and/or DOG-1. Actually, sometimes it must rely on analysis of gene, when it is negative for the foregoing two markers [11]. Still, only complete surgical resection of GIST is curative, although molecular target drugs, such as imatinib mesylate, are utilized as adjuvant and neoadjuvant therapy [10].

Case report

July 25th 2013, a 50-year-old male was admitted to

our hospital (Department of Gastrointestinal Surgery, the Affiliated Hospital, Luzhou Medical College, China) with complaint of a gradually increased lump in abdomen for 5 months. He had decreased appetite, low fever, and vomiting. He also gave history of an episode of melena 3 months prior to present illness, which was not diagnostically evaluated.

On general examination his vitals were stable and the systemic examination was normal. Clinical abdominal examination revealed that a tremendous solid mass, about the size of a football, located mainly in the left upper quadrant, with restricted mobility and minimally tenderness. Laboratory results were unremarkable with the exception of a mild anaemia. Plain abdominal radiography was negative. Abdominal CT scan showed a 37 × 12 cm tumoral mass beneath the diaphragm and the back of stomach, resulting in an obvious push of partial intestinal tract into the lower quadrant (Fig. 1).

Unfortunately, one day after admission, the patient suddenly presented with vomiting, persistent abdominal pain, high fever, and a slightly decrease of tumor. Abdominal examination revealed distension, board-like rigidity, rebound tenderness and inaudible bowel sounds. Diagnostic abdominocentesis was positive.

A provisional clinical diagnosis of acute abdomen was made and the perforation of GI tract could be the leading cause. A laparotomy was urgently underwent, demonstrating acute localized peritonitis caused by a ruptured

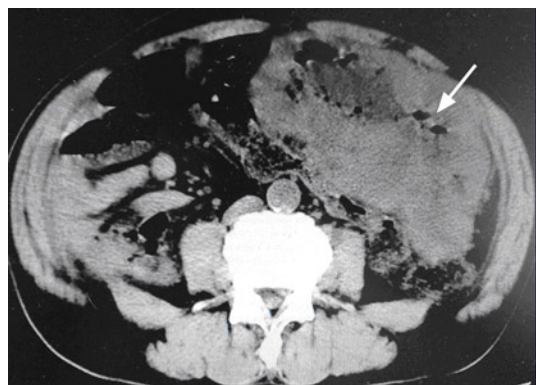


Fig. 1 The abdominal CT scan showed a heterogenous mass (arrow) with zone of parenchymal necrosis occupying most part of the left abdominal cavity

gastric tumor of maximum diameter of 3–5 cm (Fig. 2). The large hypervascularized mass, arising from the distal part of the stomach, occupied almost the entire abdominal cavity. No other significant findings such as loco-regional or remote metastasis were found at this time. Under the cautious intra-operational evaluation a subtotal gastrectomy was carried out and the tumor was excised intact. The surgical margins were then found to be tumor free.

The complete mass was a well-circumscribed tumor weighting 7500 g and measuring 37 cm × 25 cm × 15 cm *ex vivo*. The solid parenchyma had focal areas of necrosis. And the perforation located in the posterior aspect of the gastric wall presented a communication with the larger cystic cavity.

The ultimate immunohistochemical staining showed positive reactivity to CD117 (Fig. 3) and DOG-1, but negative to S-100 and SMA, and nuclear atypia was prominent with mitotic activity of 10 mitotic counts/high-power field (HPF), thus suggesting the diagnosis of gastric GIST with high risk of malignancy.

The patient had an uneventful postoperative course and was discharged on the tenth postoperative day. The patient was then put on imatinib mesylate 400 mg daily, and followed up in the outpatient clinic without any signs of recurrence 6 months after surgery.

Discussion

GISTs are infrequent, only less than 1% of all GI tumors [12], but are the most common mesenchymal neoplasms of the GI tract [13]. Because of the exophytic behavior, GISTs are clinically silent until they reach a significant size [14]. Although the diagnostic procedure includes several examinations, such as computer tomography, sonography, endoscopic ultrasound and angiography, none of them can make the completely correct diagnosis. Because of the danger of potential tumor rupture or intraperitoneal

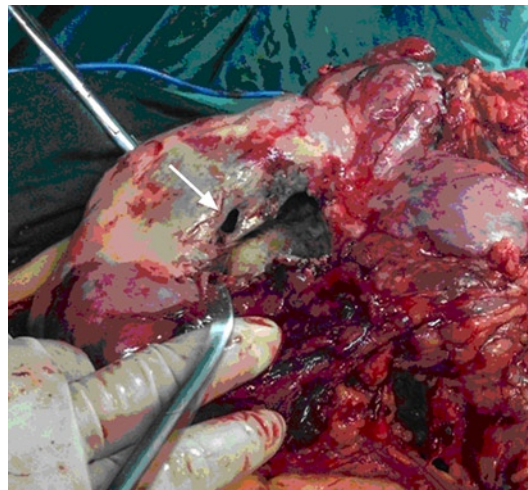


Fig. 2 A large hypervascularized mass, arising from the distal part of the stomach, demonstrated a spontaneous rupture (arrow) with maximum diameter of 3–5 cm




Fig. 3 Immunohistochemical staining of the resected tumor tissue revealed positive reactivity to CD117

migration, the preoperative biopsy is not recommended as a routine inspection unless to rule out differential diagnoses like lymphoma or other benign or malignant neoplasms [10, 15, 16].

Immunohistochemical and gene detection can identify the final diagnose of GIST [11, 17], since 94%–98% positive for CD117 which was the production of mutation of *c-kit* gene and 94%–96% positive for DOG-1 [11], and approximately 80% of GISTs negative for CD117 harbor *PDGRA* gene mutations [17].

GISTs can be categorized as low or high-risk tumors by taking into account the possibility of recurrence, metastasis or tumor-related death. Risk stratification of GISTs was generally thought to depend on the size, the site, and the mitotic rate [14]. But it was determined, according to National Institutes of Health consensus criteria revised by Joensuu, that rupture of the tumor into the criterion as an

Table 1 Risk stratification of gastrointestinal stromal tumors

Risk classification	Tumor size (cm)	Mitotic counts (/50HPF)	Primary tumor site
Very low	< 2	≤ 5	Any
Low	2–5	≤ 5	Any
Intermediate	2–5	> 5	Gastric
	< 5	6–10	Any
	5–10	≤ 5	Gastric
High	Any	Any	Tumor rupture
	> 10	Any	Any
	Any	> 10	Any
	> 5	> 5	Any
	2–5	> 5	Non-gastric
	5–10	≤ 5	Non-gastric

independent factor (Table 1) [18].

Tyrosine kinase inhibitors, such as imatinib mesylate, are recommended for GISTs that are marginally resectable or resectable with risk of significant morbidity. And imatinib used pre- and post-operatively can help improve resectability, reduce surgical morbidity and recurrence, as well as prolong survival [10]. Nevertheless surgical resection still plays an irreplaceable role in curing GISTs.

Although multidisciplinary methods were conducted to treat GISTs, the prognosis is still dismal when the tumors present with symptoms or signs such as rupture, multifocal location or metastatic lesions. The five-year survival of the patients with localized or locally advanced tumors was about 46%, compared to 0% of the patients with metastatic tumors or multifocal tumors. And it decreased to 24% when rupture or perforation occurred [19].

Although giant gastric GISTs are not common, the complications such as tumor rupture or perforation may be fatal. This case highlights that patients considering bulky GISTs must be managed carefully to prevent serious and complex complications. Adjuvant and neoadjuvant therapies with tyrosine kinase inhibitors are still investigated, they have considerable activity in patients with advanced disease such as perforated or ruptured tumors and should thus be considered as an adjuvant to surgery. In any case, a R0 resection remains the mainstay for GISTs and adjuvant therapy with imatinib must be considered.

References

- Kang KY, Lee W. Gastrointestinal stromal tumor with extensive lymphatic metastasis: a case report. *J Gastric Cancer*, 2013, 13: 192–195.
- Mehta RM, Sudheer VO, John AK, *et al.* Spontaneous rupture of giant gastric stromal tumor into gastric lumen. *World J Surg Oncol*, 2005, 3: 11–15.
- Miettinen M, Lasota J. Gastrointestinal stromal tumors (GISTs): definition, occurrence, pathology, differential diagnosis and molecular genetics. *Pol J Pathol*, 2003, 54: 3–24.
- Behranwala KA, Spalding D, Wotherspoon A, *et al.* Small bowel gastrointestinal stromal tumours and ampullary cancer in Type 1 neurofibromatosis. *World J Surg Oncol*, 2004, 2: 1–4.
- Rubin BP, Singer S, Tsao C, *et al.* KIT activation is a ubiquitous feature of gastrointestinal stromal tumors. *Cancer Res*, 2001, 61: 8118–8121.
- Heinrich MC, Corless CL, Duensing A, *et al.* PDGFRA activating mutations in gastrointestinal stromal tumors. *Science*, 2003, 299: 708–710.
- Medeiros F, Corless CL, Duensing A, *et al.* KIT-negative gastrointestinal stromal tumors: proof of concept and therapeutic implications. *Am J Surg Pathol*, 2004, 28: 889–894.
- Lin YL, Tzeng JE, Wei CK, *et al.* Small gastrointestinal stromal tumor concomitant with early gastric cancer: a case report. *World J Gastroenterol*, 2006, 12: 815–817.
- Huang ZG, Zhang XS, Huang SL, *et al.* Endoscopy dissection of small stromal tumors emerged from the muscularis propria in the upper gastrointestinal tract: Preliminary study. *World J Gastrointest Endosc*, 2012, 4: 565–570.
- Beham AW, Schaefer IM, Schuler P, *et al.* Gastrointestinal stromal tumors. *Int J Colorectal Dis*, 2012, 27: 689–700.
- CSOC. Consensus on diagnosis and treatment for gastrointestinal stromal tumor in China of CSCO, 2013. *Chin Clin Oncol (Chinese)*, 2013, 18: 1030–1037.
- Lai EC, Lau SH, Lau WY. Current management of gastrointestinal stromal tumors—a comprehensive review. *Int J Surg*, 2012, 10: 334–340.
- Demetri GD, von Mehren M, Antonescu CR, *et al.* NCCN Task Force report: update on the management of patients with gastrointestinal stromal tumors. *J Natl Compr Canc Netw*, 2010, 8: S1-S41.
- Cappellani A, Piccolo G, Cardi F, *et al.* Giant gastrointestinal stromal tumor (GIST) of the stomach cause of high bowel obstruction: surgical management. *World J Surg Oncol*, 2013, 11: 172–175.
- Tateishi U, Miyake M, Maeda T, *et al.* CT and MRI findings in KIT-weak or KIT-negative atypical gastrointestinal stromal tumors. *Eur Radiol*, 2006, 16: 1537–1543.
- Laurini JA, Carter JE. Gastrointestinal stromal tumors: a review of the literature. *Arch Pathol Lab Med*, 2010, 134: 134–141.
- Joensuu H. Risk stratification of patients diagnosed with gastrointestinal stromal tumor. *Hum pathology*, 2008, 39: 1411–1419.
- Crosby JA, Catton CN, Davis A, *et al.* Malignant gastrointestinal stromal tumors of the small intestine: a review of 50 cases from a prospective database. *Ann Surg Oncol* 2001, 8: 50–59.
- Liu SL, Song ZF, Li W, *et al.* A clinicopathologic and immunohistochemical study of gastrointestinal stromal tumors based on 122 cases. *Chinese-German J Clin Oncol*, 2010, 9: 597–600.