

# Efficacy of DR, CT and MRI in bone tumors

Yanjiao Zhang, Xuefeng Cui, Changcheng Li, Shenjiang Li

Department of Imageology, The Eighty-eighth Military Hospital, Tai'an 271000, China

Received: 24 December 2013 / Revised: 15 January 2014 / Accepted: 5 March 2014  
© Huazhong University of Science and Technology 2014

**Abstract Objective:** The aim of the study was to investigate the efficacy of digital radiography (DR), computed tomography (CT) and magnetic resonance imaging (MRI) in bone tumors. **Methods:** Fifty-five patients with histologically confirmed bone tumors underwent imaging examinations. Fifty-five patients were performed DR, 21 CT and 20 MRI. **Results:** DR of 51 patients clearly revealed bone changes. DR of 40 patients well showed marginal. Twenty tumors appeared periosteal reaction on DR and 19 calcification on DR. CT scan of 21 patients clearly depicted bone changes, marginal and calcification and CT scan of 8 revealed periosteal reaction. MRI scan of 20 patients all showed marginal and soft-tissue mass and bone marrow edema was prominent in 8 patients. **Conclusion:** DR is the first imaging approach for bone tumors. CT well reveal the extent and minute structure of the bone tumors, the extent, soft-tissue mass and bone marrow edema are more dramatically demonstrated on MRI imaging. DR integrates with CT and MRI, is helpful in diagnosis of bone tumors.

**Key words** bone tumor; digital radiography (DR); computed tomography (CT); magnetic resonance imaging (MRI)

The incidence of bone tumors among all tumors is 2%–3%<sup>[1]</sup> and rising in recent years. Imaging approaches play an important role in the diagnosis of bone tumors. With advance of technology, digital radiography (DR), computed tomography (CT) and magnetic resonance imaging (MRI) can now offer more information in the study of bone tumors than before thanks to its higher specificity in detecting tumor morphologic hallmarks and blood flow of neoplasm. Currently, DR, CT and MRI have been widely used in our country. How to apply these advanced equipments to the diagnosis of the bone tumors has become an important issue. This study is to evaluate the clinical efficacy of DR, CT and MRI in the diagnosis of bone tumors.

## Materials and methods

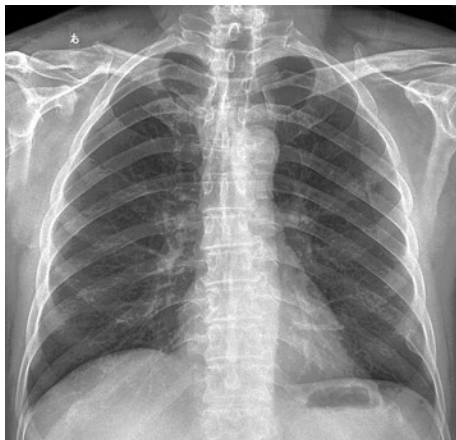### Patients

Patients were selected according to the following criteria: (a) being confirmed histologically, (b) underwent DR, CT or MRI, and (c) absence of contraindication to the administration of contrast materials. Two patients because of substantial artifact were excluded from the study. Fifty-five patients with bone tumor met the criteria between 2004 and 2006 were selected. Of these patients, 3 patients with myeloma (2 males, 1 female, and mean age 51.5 years), 6 patients were with osteochon-

droma (4 males, 2 females, and mean age 17.5 years), 13 patients with metastasis (7 males, 8 females, and mean age 50.5 years), 2 patients with synovia sarcoma (2 males, and mean age 31 years), 8 patients with bone giant cell tumor (4 males, 4 females, and mean age 35.5 years), 4 patients with hemangioma (2 males, 2 females, and mean age 43.5 years), 5 patients with osteosarcoma (2 males, 3 females, and mean age 24.5 years), 7 patients with non-ossifying fibroma (1 male, 6 females, and mean age 20.5 years), 2 patients with Ewing's sarcoma (1 male, 1 female, and mean age 10.5 years), 2 patients with chondroblastoma (1 male, 1 female, and mean age 16 years), and 1 patient was with fibroma (1 male, age 17 years), 1 patient with lipoma (1 male, age 55 years), 1 patients with benign fibrous histiocytoma (1 male, age 51 years). All cases were confirmed by the surgical pathology or puncture biopsy.

### Protocol

DR was performed with DX500 DR machine. All CT scans were obtained with a commercially available system (LightSpeed, General Electric Medical Systems, and VCT). Spiral CT sequence was performed with 120 kV, 80–350 mA, field of view (FOV) 250 mm, a 0.625 mm collimation, and pitch 0.984:1. The contiguous images were reconstructed with 5-mm slice thickness, from the volumetric data using the standard algorithm (soft tissues window setting, window width 350 Hu, window center 40 Hu) and bone algorithm (bone window setting, window width 2000 Hu, window center 400 Hu).



**Fig. 1** The patient was a 59-year-old man with rib benign fibrous histiocytoma. DR showed local expansive well defined bone destruction in left eighth rib with ossification margin and nodular-like calcification inside and without obvious periosteal reaction

All MR studies were performed by using a 1.5-T superconducting magnet and a array body coil. The scan (4 mm slice thickness,  $256 \times 256$  matrix pixels,  $24 \text{ cm} \times 38 \text{ cm}$  field-of-view) included transversal coronary and sagittal. The fast spin echo sequences (TSE) parameters for the T1 weighted imaging were TR = 616 ms, TE = 20 ms and T2 weighted imaging were TR = 4620 ms, TE = 103 ms. The fat suppressed sequence parameters for T2 weighted imaging were TR = 4940 ms, TE = 103 ms, and TI = 140 ms.

## Results

### DR findings

Of these 55 cases, DR of 51 patients displayed bone destruction, calcification or ossification clearly, but it was

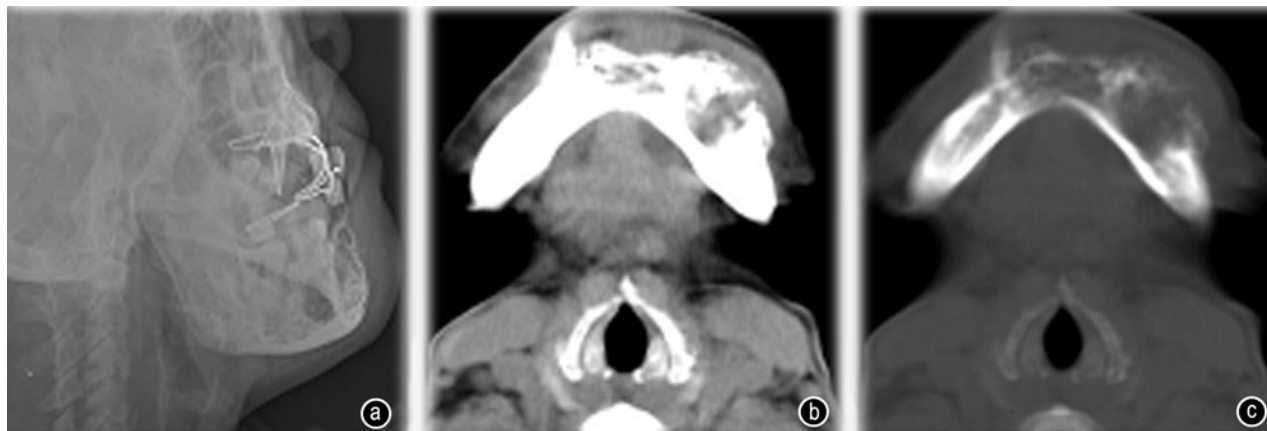difficult for DR to show bone changes of small spinal tumor. DR of 4 cases couldn't reveal the bone changes. DR of 40 cases showed margin clearly but was difficult, in some extent, in revealing the margin of small tumors in the spine, skull, pelvis and other complicated organs. Periosteal reaction, even the mild periosteal reaction, of 20 cases were clearly depicted by DR. DR showed calcification with different sizes in 19 patients, but was difficult in revealing the tiny calcification clearly. DR could not display the needle-like calcification in 2 cases. DR was difficult to display soft-tissue mass in most tumors (Fig. 1 and Fig. 2a).

### CT findings

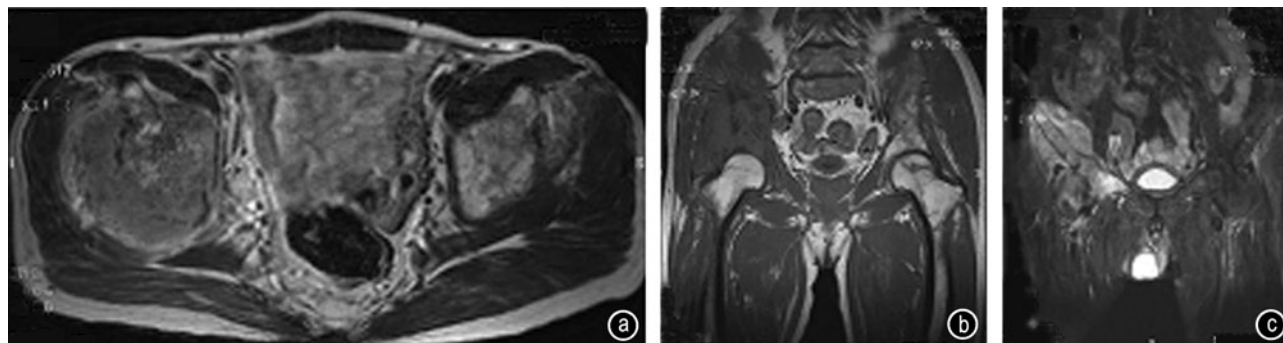
Bone changes (destruction, calcification or ossification), margin, and different sizes of calcifications were revealed clearly on CT image in 21 patients. CT had obvious advantages in showing these changes, especially for tip-like calcification. CT clearly showed the periosteal reaction in 8 cases, but was difficult in revealing the mild periosteal reaction. CT couldn't reveal the mild irregular periosteal reaction depicted by DR in one patient. CT could reveal soft-tissue mass in most tumors, however, value of CT in showing the relationship between soft-tissue mass, adjacent tissues, and organs was limited (Fig. 2b and 2c).

### MRI findings

MRI was performed in 20 patients. The lesions showed hypointense mainly in T1WI and hyperintense in T2WI in 16 patients. In 4 cases, the lesions showed hypointense mainly in T1WI and isointense and hypointense in T2WI. MRI with high soft tissues resolution showed margin and soft tissue mass of tumors clearly in 20 patients. The relationships between tumor, adjacent tissues, and organs were depicted clearly on the axial, sagittal and



**Fig. 2** The patient was a 50-year-old woman with maxilla hemangiomas. (a) DR showed maxilla irregular well defined bone destruction; (b) CT image obtained with a soft tissue window setting showed irregular bone destruction with poorly defined soft-tissue mass; (c) CT image obtained with a bone window setting showed irregular destruction with residual bone inside



**Fig. 3** The patient was a 57-year-old man with ilium metastasis from lung adenocarcinomas. (a) The axial T1WI image showed irregular bone destruction with irregular soft-tissue mass in right iliac and the lesion showed hypointense; (b) The coronal T1WI image showed irregular bone destruction with irregular soft-tissue mass in right iliac and the lesion showed hypointense; (c) The coronal T1WI image showed irregular bone destruction with irregular soft-tissue mass in right iliac and the lesion showed hyperintense

coronal images. MRI showed the corresponding bone marrow edema on fat suppression sequence T2WI images in 8 patients. But it was difficult in some extent to show calcification by MRI without the combination of DR and CT (Fig. 3).

## Discussion

### The role of DR in the diagnosis of bone tumors

The skeletal system has a good nature contrast. X-ray and CT played an important role in the diagnosis of bone tumors. Since the advent of DR in 1982, it has been developed by many companies. DR becomes very popular in China currently. Comparing with traditional radiograph, DR with higher contrast resolution and lower radiation doses is superior to traditional radiograph [2].

DR has four advantages in diagnosis of bone tumors. First, DR with high spatial resolution can show the mild periosteal reaction. CT could not reveal the periosteal reaction in one patient, while the DR showed mild irregular periosteal reaction. Second, bone changes and different sizes of calcifications in most bone tumors were showed on DR clearly. Third, DR shows a good three-dimensional imaging of bone tumors. Fourth, DR is cheap relatively.

There are three pitfalls in the diagnosis of bone tumors by DR. First, DR of 40 cases showed margin clearly but is difficult, in some extent, to reveal the margin of small tumors in the spine, skull, pelvis and other complicated organs. DR of 4 cases couldn't reveal the bone changes. Second, DR is difficult in revealing the tiny calcification clearly. Third, the soft tissue masses could not be seen clearly in DR.

Although DR have some shortcomings in the diagnosis of bone tumors, DR also have great advantages, especially in the diagnosis of limbs tumors. In many cases, the defined diagnosis could be made by DR, so it is still the first choice for in the diagnosis of bone tumors.

### The role of CT in the diagnosis of bone tumors

CT, especially the multi-detector spiral CT (MS-CT) with higher temporal resolution and lower radiation doses, has prominent advantages in showing the morphologic hallmarks and blood flow of neoplasm [1,3,4]. Because images can be reconstructed from any orientation by MS-CT workstation, MS-CT has greater advantage in depicting the morphologic hallmarks and blood flow of bone tumors [1,5,6].

There were three advantages in the diagnosis of bone tumors by CT. First, MS-CT can accurately show the bone changes and lesion margin. Even small tumors in the spine, skull, pelvis and other complicated organs can be clearly displayed. Second, the different sizes of calcifications, even a slight calcification, can be revealed on CT. Third, CT can display soft-tissue mass in most tumors.

Disadvantages of CT are in revealing the mild periosteal reaction.

CT plays an important role in the diagnosis of bone tumor and, with the popularization of multi-detector spiral CT, CT will receive more attentions.

### The role of MRI in the diagnosis of bone tumors

With the advance of MRI technology, MRI played more important role in the diagnosis of bone tumors. Many scholars have done a lot of researches on this subject [4,7-9].

MRI, with high soft tissue resolution and ability of scans from any orientation, has four advantages in diagnosis of bone tumors. First, MRI can display the extent of lesions and soft tissue mass accurately. Second, MRI can show the relationship between tumor and adjacent tissues and organs clearly. Third, MRI can reveal the corresponding bone marrow edema.

Disadvantages of MRI are that it is difficult in some extent to show calcification by MRI without the combination of DR and CT.

### The necessity of the combination DR and CT with MRI

Diagnosis is mainly based on age, location, the pattern of bone changes, periosteal reaction, and the tissue characteristics. How to fully display the pattern of bone changes, periosteal reaction, and the tissue characteristics of bone tumours has become the important topic and is also the most important step of imaging diagnosis.

DR had obvious advantages in showing the mild periosteal reaction. Bone changes caused by bone tumors and calcifications also could be showed on DR clearly. CT has good performance in revealing the bone changes, different size of calcifications and soft tissue mass. The lesions extent, the relationship between tumor and adjacent tissues and organ, and the corresponding bone marrow edema can be showed on MRI clearly. The combination DR and CT with MRI is helpful in diagnosing of bone tumors.

In a word, it will improve the accuracy in imaging diagnosis of bone tumors to show the characteristics of bone tumors clearly and accurately by combination DR and CT with MRI.

### References

1. Wang J, He BJ, Jiang ZB, *et al.* Diagnostic value of multislice spiral CT and MRI in detection of tumor recurrence after liver transplantation for hepatocellular carcinoma. *Chin J Oncol (Chinese)*, 2009, 31: 691–696.
2. Even-Sapir E, Flusser G, Lerman H, *et al.* SPECT/multislice low-dose CT: a clinically relevant constituent in the imaging algorithm of non-oncologic patients referred for bone scintigraphy. *J Nucl Med*, 2007, 48: 319–324.
3. Li SJ, Zhao Y, Zhu Y, *et al.* Preliminary assessing no-surgical treatment response in bronchogenic carcinoma with double-phase contrast material-enhanced computed tomography. *Chinese-German J Clin Oncol*, 2009, 8: 152–155.
4. Ghanem N, Uhl M, Brink I, *et al.* Diagnostic value of MRI in comparison to scintigraphy, PET, MS-CT and PET/CT for the detection of metastases of bone. *Eur J Radiol*, 2005, 55: 41–55.
5. Li SJ, Zhao Y, Wu SC, *et al.* Clinical value of CR, CT and MRI in spinal tuberculosis. *Ortho J Chin (Chinese)*, 2007, 15: 1002–1004.
6. Sun MY, Wang SW. MR perfusion and diffusion imaging for the diagnosis of benign and malignant bone tumors. *Chinese-German J Clin Oncol*, 2008, 7: 352–357.
7. Römer W, Nömayr A, Uder M, *et al.* SPECT-guided CT for evaluating foci of increased bone metabolism classified as indeterminate on SPECT in cancer patients. *J Nucl Med*, 2006, 47: 1102–1106.
8. Layer G, Steudel A, Schüller H, *et al.* Magnetic resonance imaging to detect bone marrow metastases in the initial staging of small cell lung carcinoma and breast carcinoma. *Cancer*, 1999, 85: 1004–1009.
9. Yu SY, Jiang ZF, Zhang L, *et al.* Chinese expert consensus statements on clinical diagnosis and treatment of malignant tumor bone metastasis and bone related diseases. *Chinese-German J Clin Oncol*, 2010, 9: 1–12.